



Sociedad Oftalmológica
de Madrid

Viernes, 15 de diciembre de 2017

Mesa redonda: Ojo seco. DEWS II

CASOS PRÁCTICOS

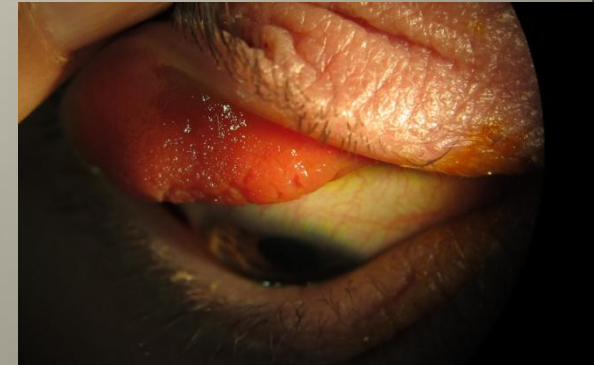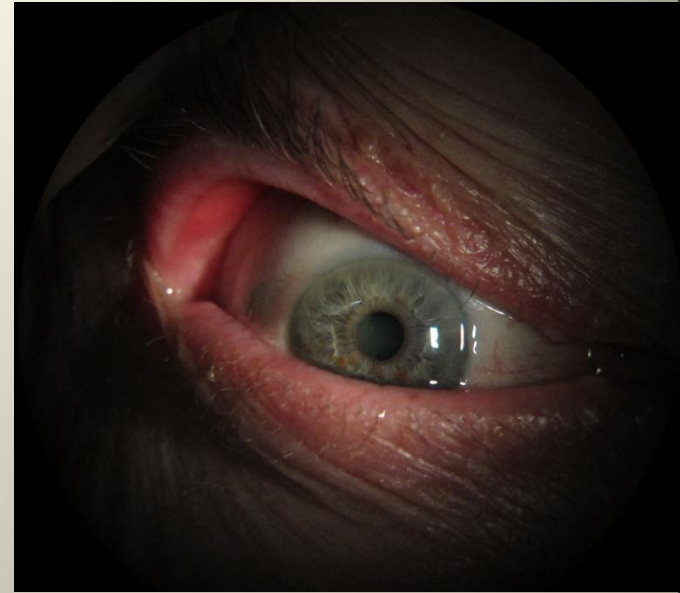


Paz Rodríguez Ausín

**Servicio de Oftalmología
Hospital Universitario de Torrejón
Clínica La Milagrosa**

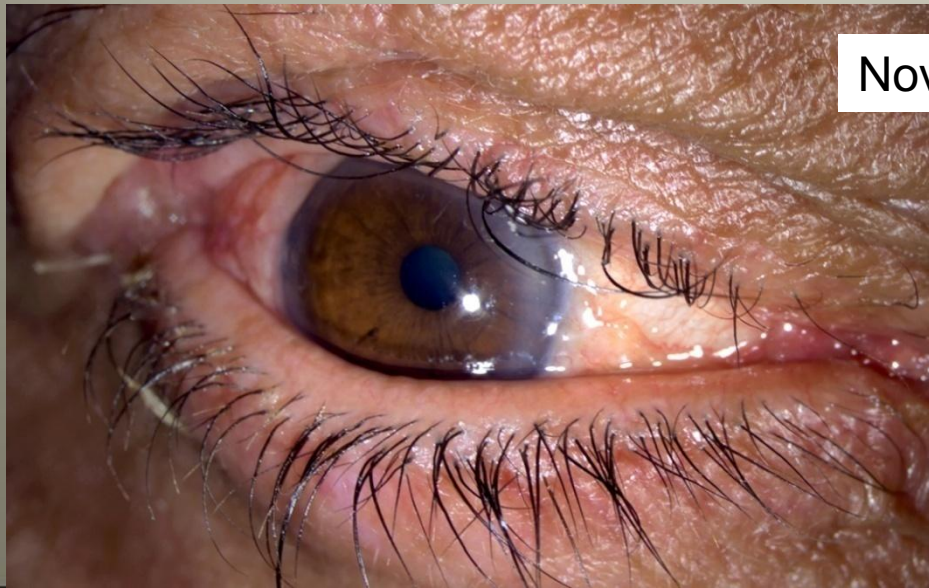CASO 1 : FLOPPY EYELID

- Apnea del sueño (SAOS) . Varones , mediana edad, alto riesgo CCVV.
- Laxitud palpebral (FE), GCA, NOIA , papiledema. Exposición , hipoxia
- Escozor , lagrimeo, ojo rojo, secreción mucosa.
- Dº: Eversión palpebral fácil. Reacción papilar tarsal. Alteración de la SO. EDE
- Tto de la SAOS: Estudio del sueño, CPAP. Dieta Lubricantes ... Cirugía .

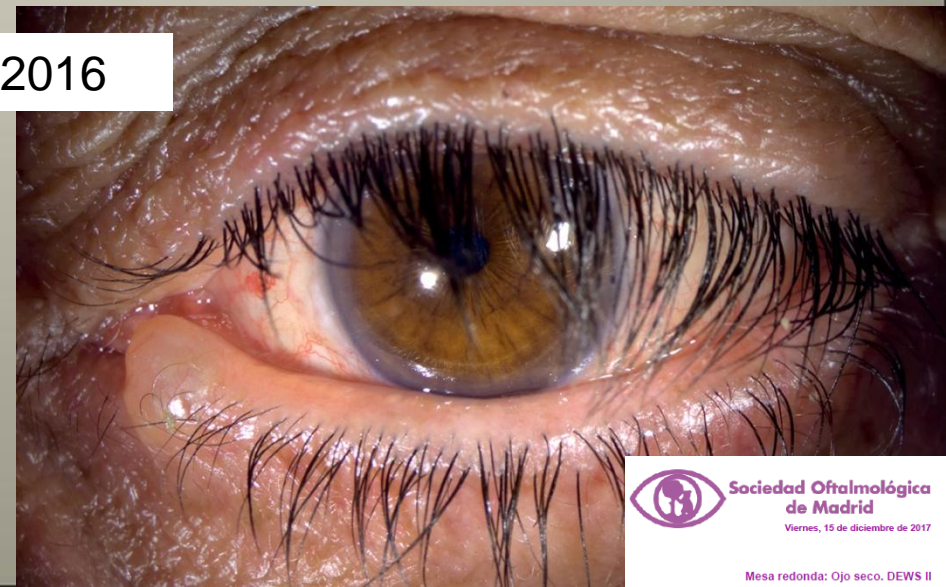


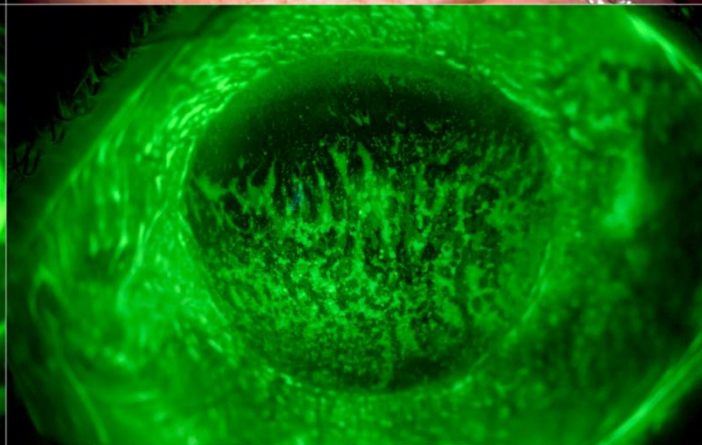
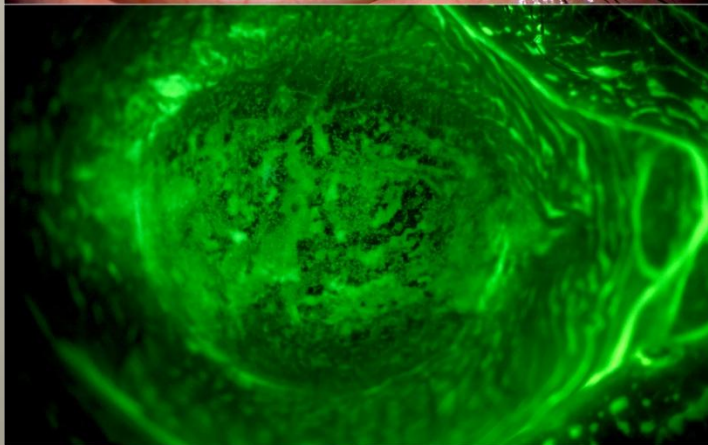
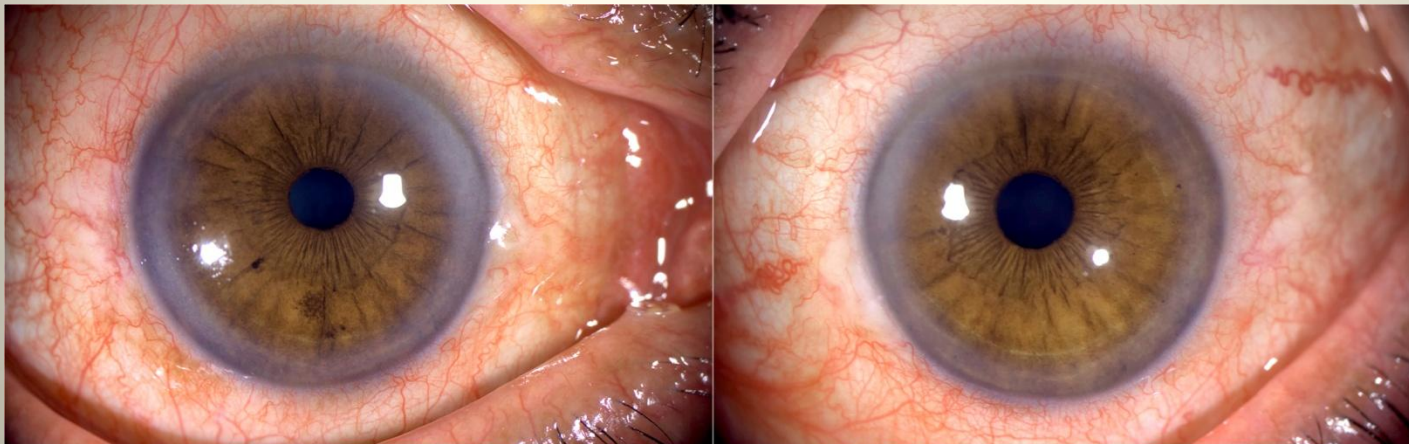
Dr. Conejero Arroyo

- 55 a. ♂ SAOS
- Ptosis de pestañas ao, Floppy eyelid
- Cirugía PSD, huso cutáneo y extirpación de cuña palpebral 2013. Tira tarsal junio 2016.
- Oj no cirugía
- Fluorometolona , Polietilenglicol+ HpGuar a demanda, HA 0.15 % a demanda, Suero Autólogo cada 6 horas, Colirio de Ciclosporina 0,1% cada 12 horas, Perfluorohexiloctano.. despues de aplicar las lágrimas.

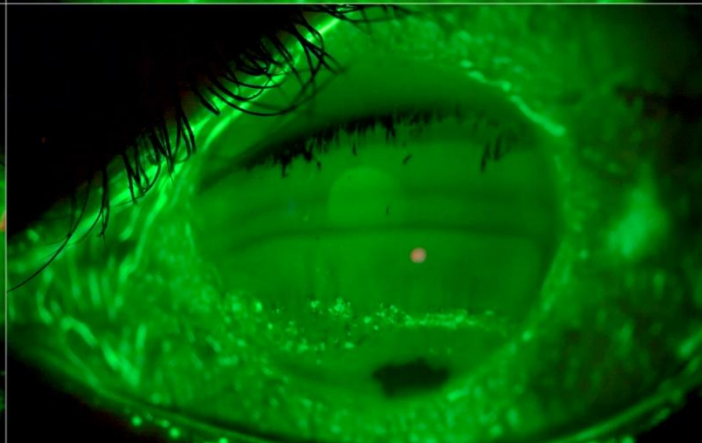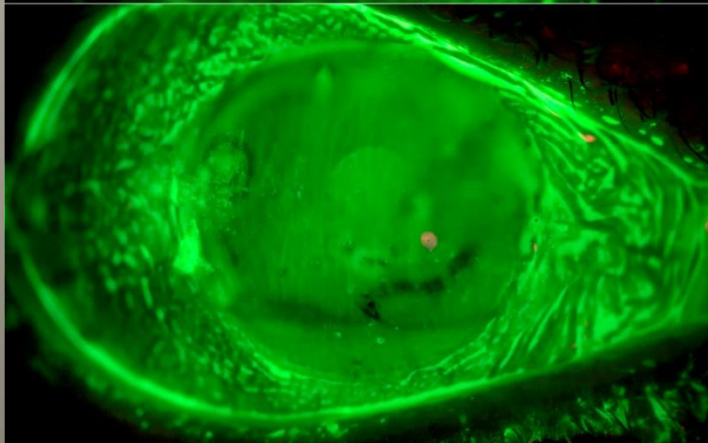


Nov2016



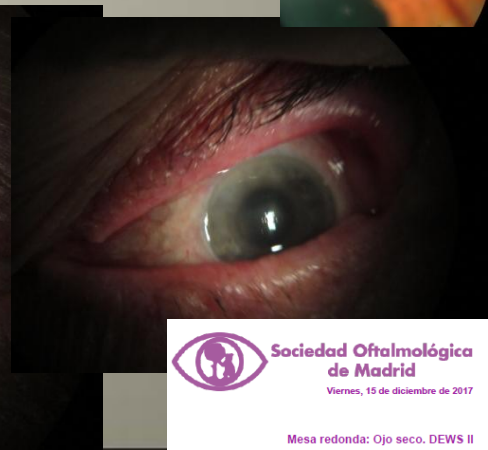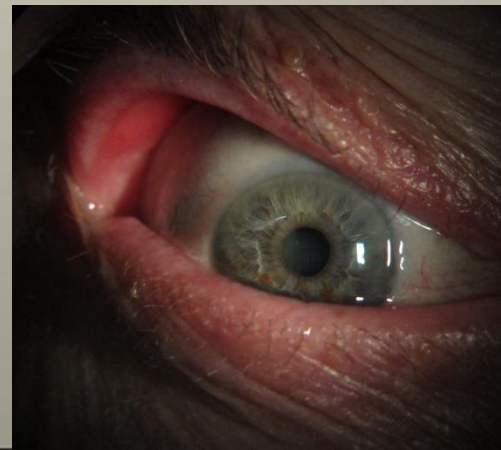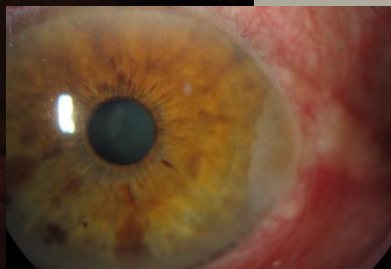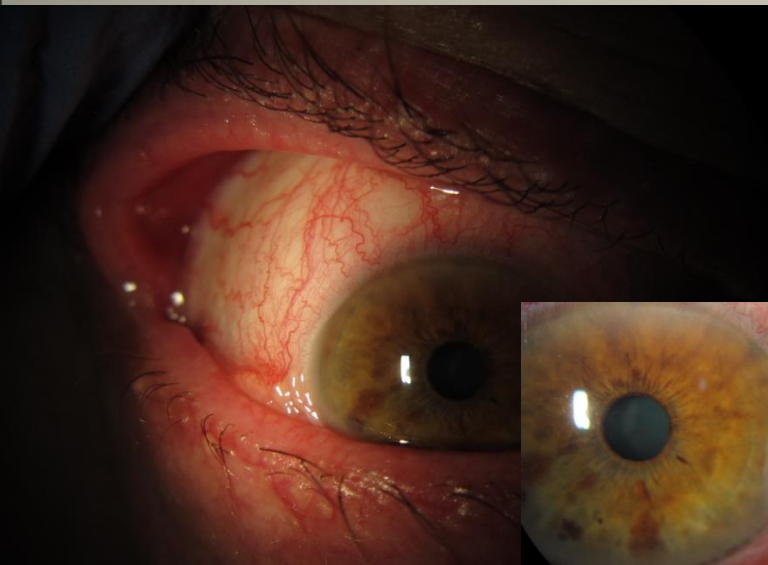
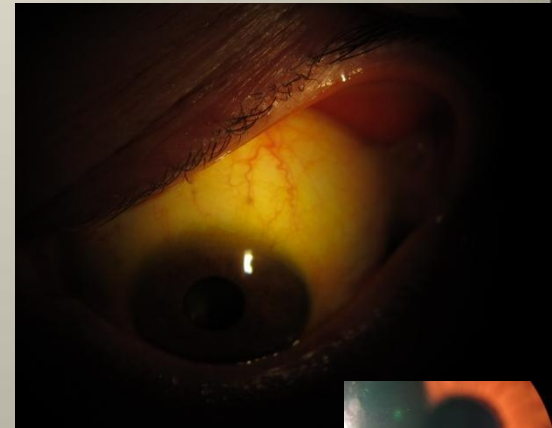
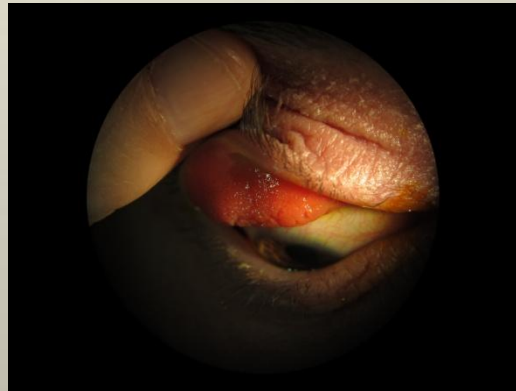


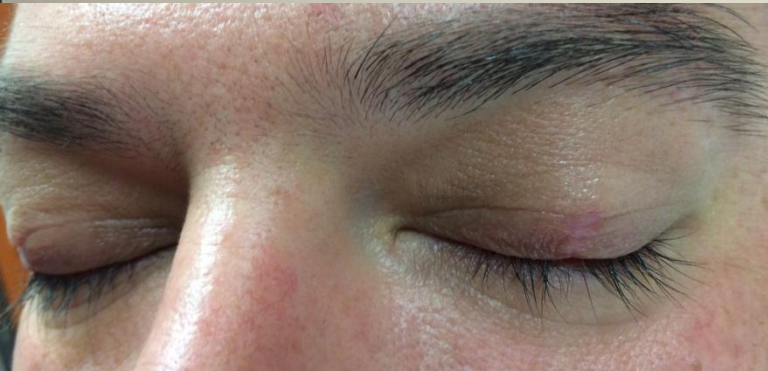Nov. 2016
Av cd/ 0,2



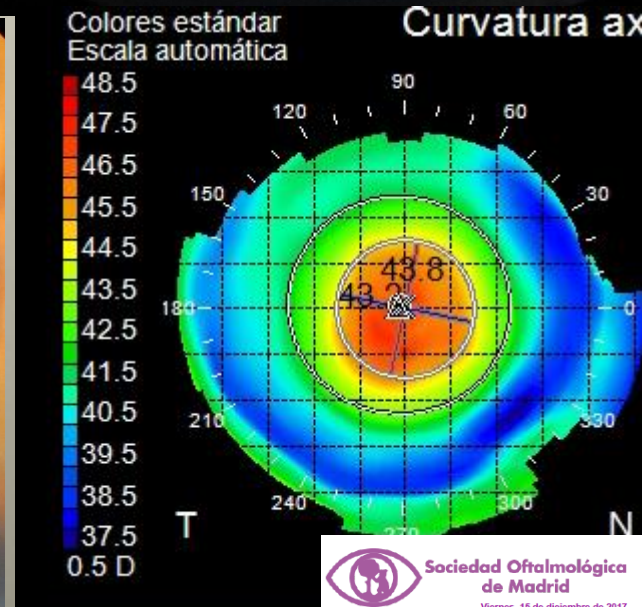
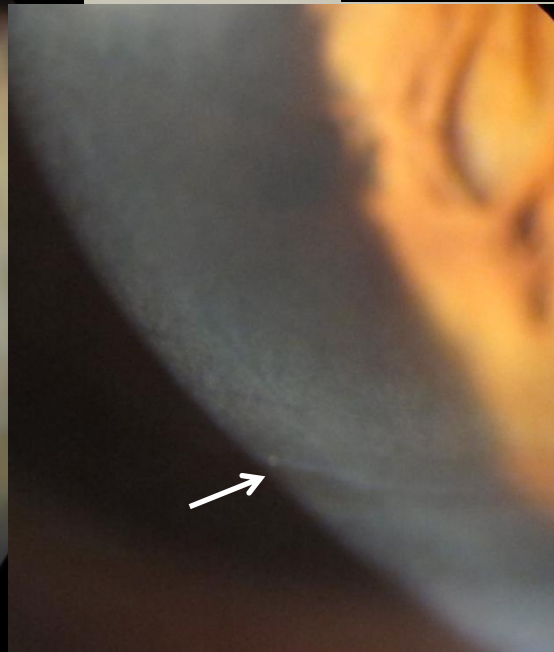
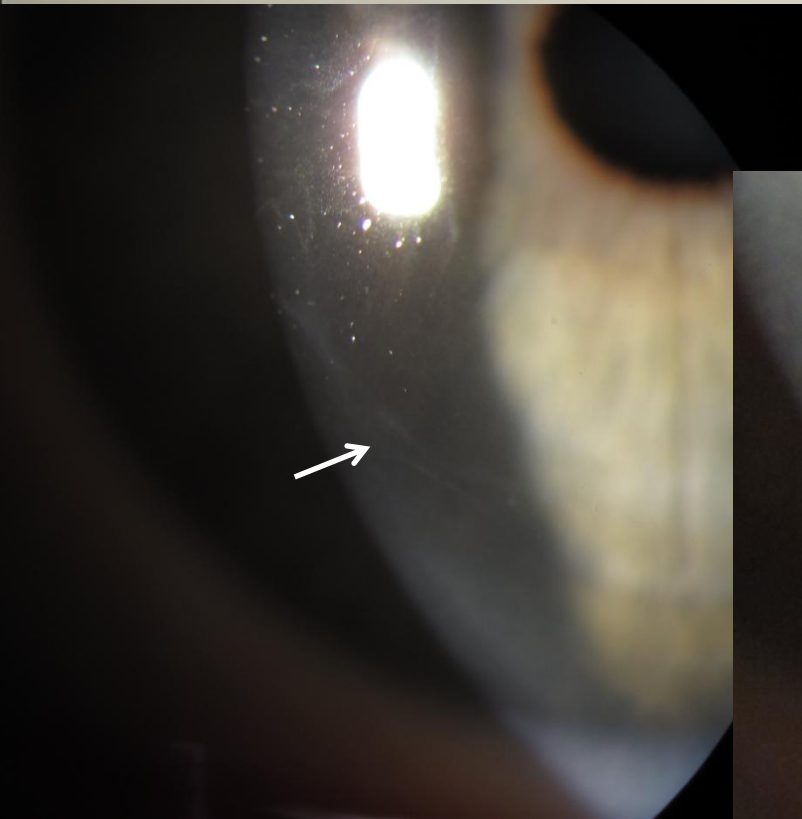
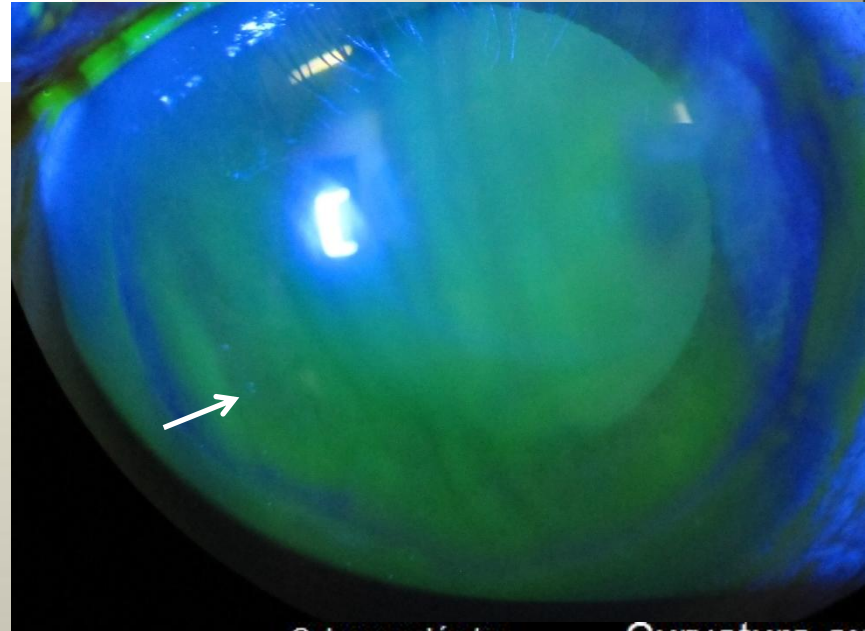
Oct. 2017
AV 0,1/0,6

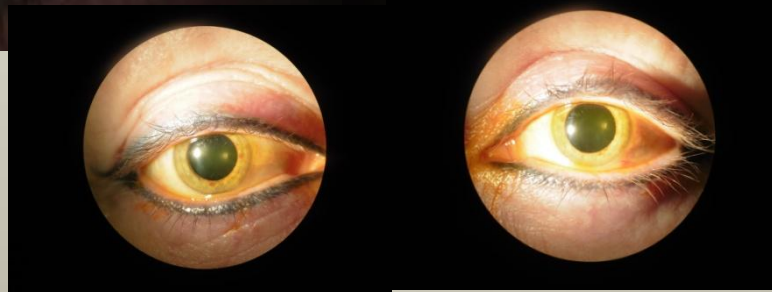
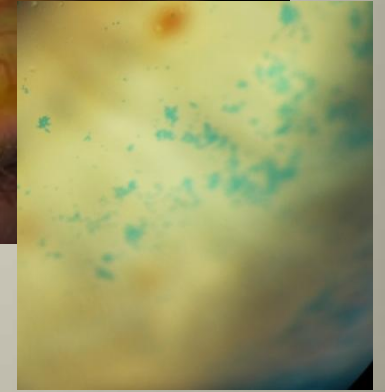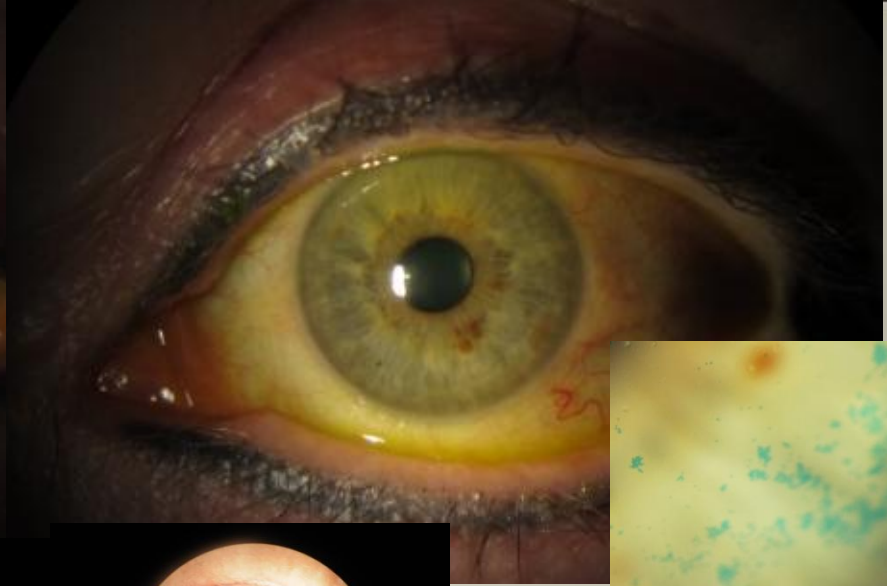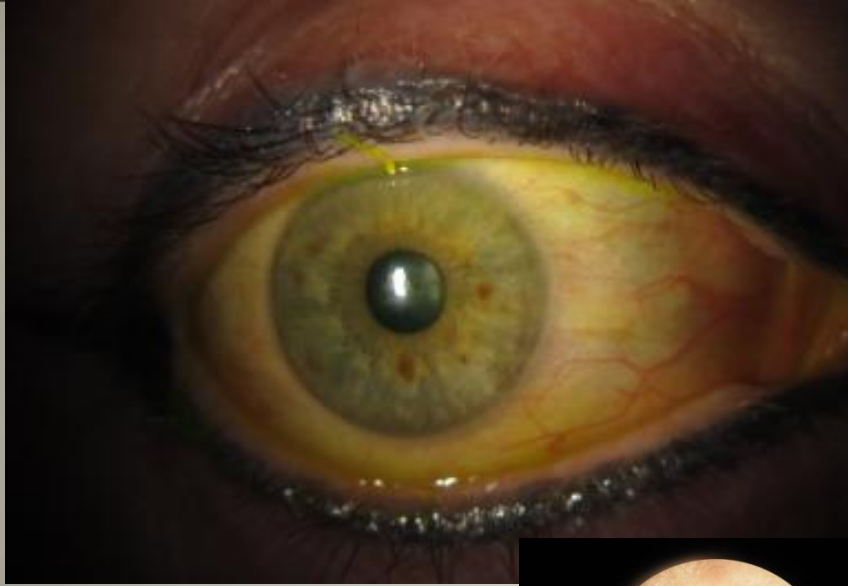
- Varón, edad media, con enrojecimiento, sensación de ce, secreción matutina, EDE.. Pensar en Floppy eyelid - Test de distracción



CASO 2: POST-LASIK

- “Amnesia frecuente” ... de Cirugías y de Refracción..H.



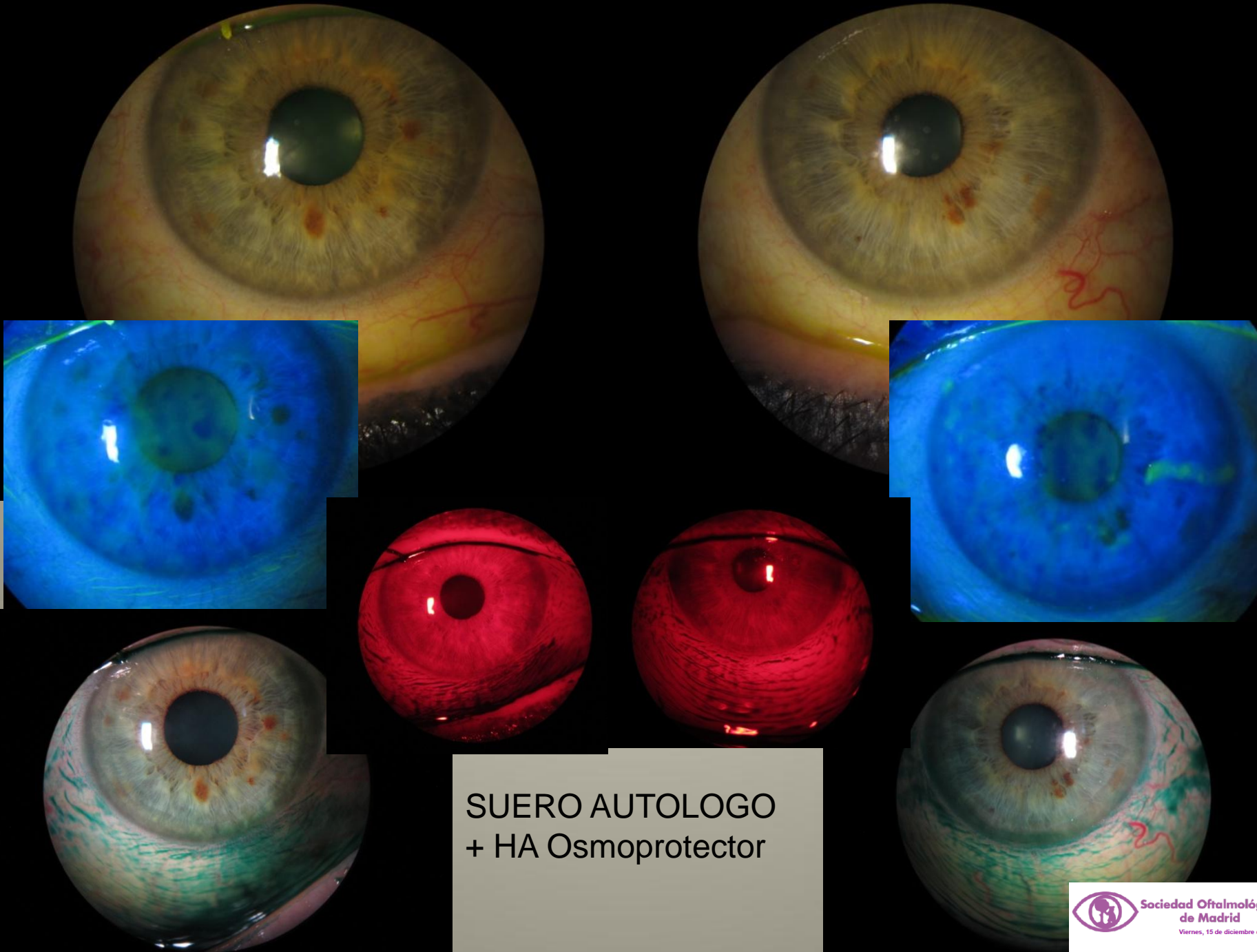


- Mujer 63 a.
- “Sin” AP oculares....Lasik OI , blefaroplastia, tatuaje
- Mala vision, escasas molestias
- MAVC OD : 0.08 (ambliope)
- MAVC OI : 2012 0.8 2017 1

Tratamiento 2012-2017

- Carmelosa, AH+ Thealosa, AH +**Carnitina**, **AH** + Heparina, **Carbomero** , PVP, Actinoquinol, Perfluorohexiloctano..
- Fluorometolona Doxiciclina Tapón.
- Antiox oral
- Lente terapéutica
- **Suero Autólogo** (2013)
- **Cacicol** (2015)





SUERO AUTOLOGO
+ HA Osmoprotector

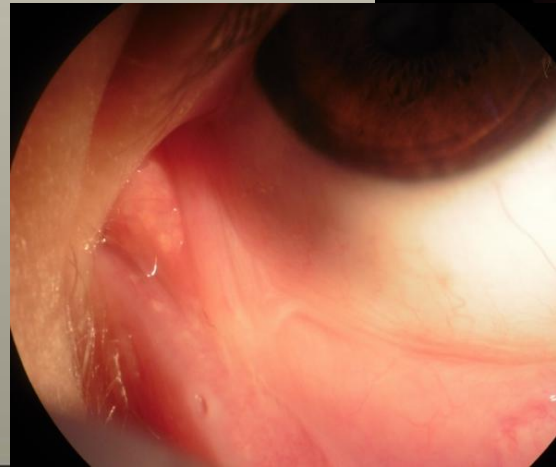
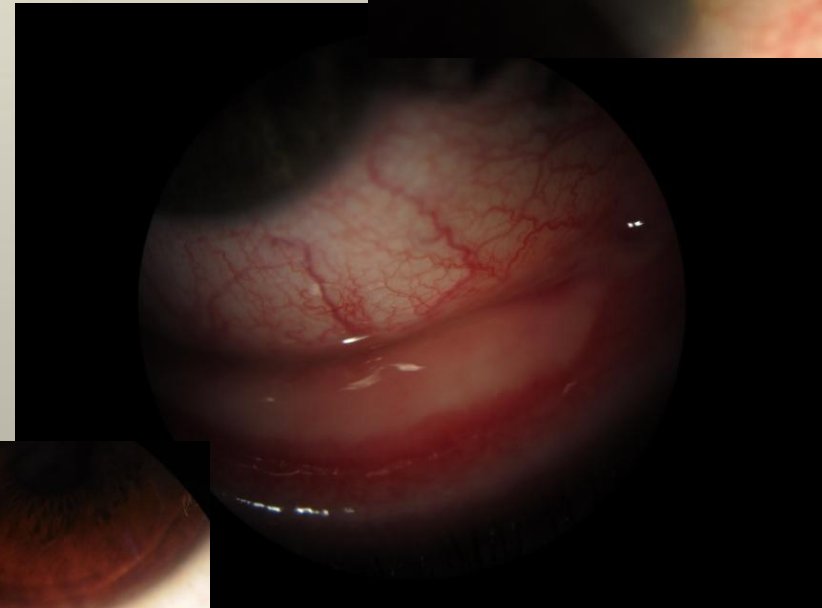
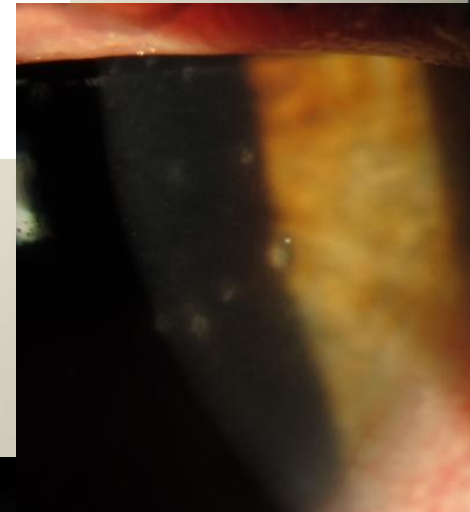
EDE + ADDE

- OJO SECO IATROGENICO :
 - POST CIRUGIA REFRACTIVA: LASIK
 - BENZODIACEPINAS/ANTIDEPRESIVOS
 - POST CIRUGIA PALPEBRAL: Exposición
- HORMONAL: MENOPAUSIA
- TATUAJE PALPEBRAL

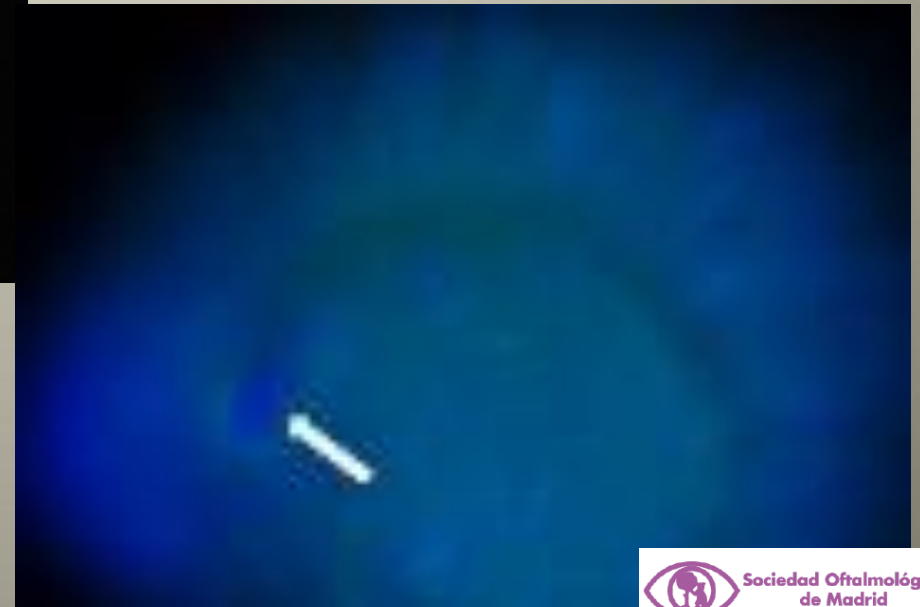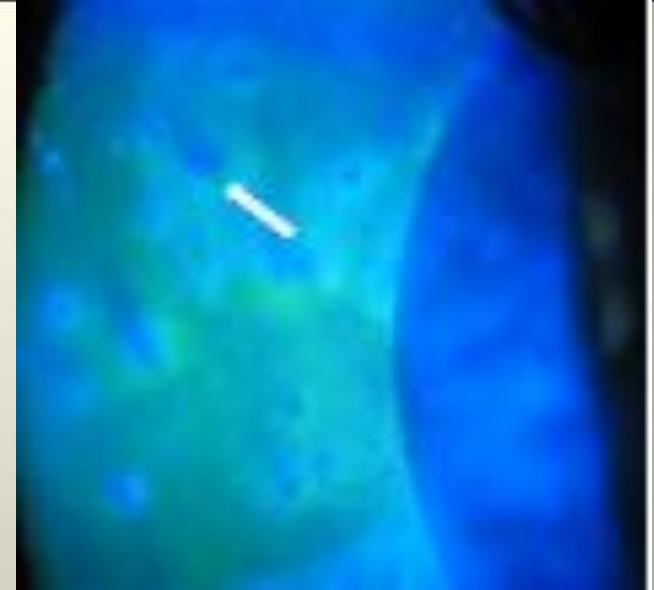
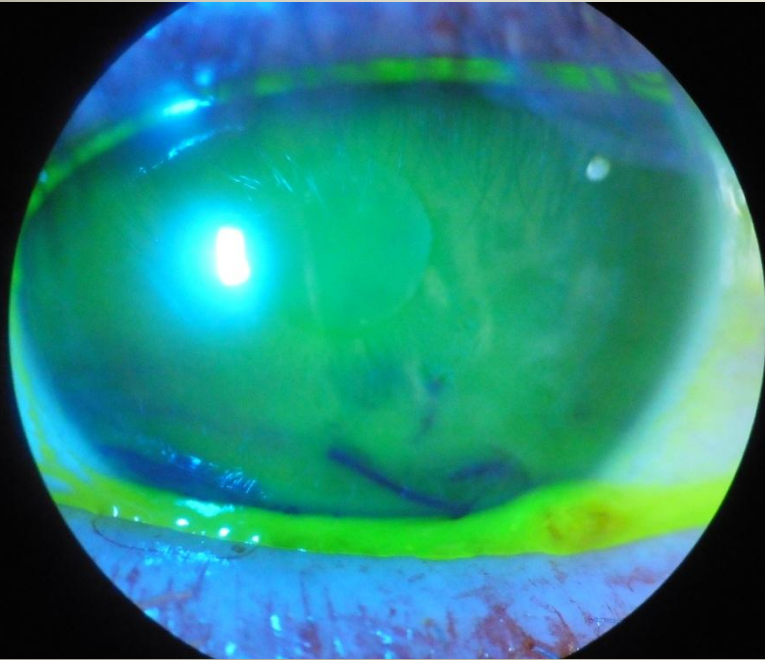


CASO 3 : Post-ADENOVIRUS

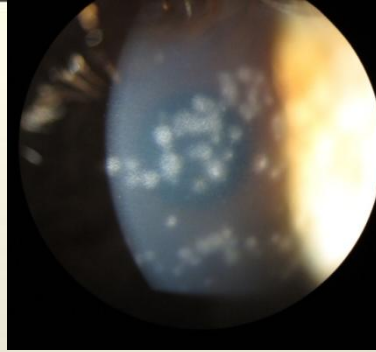
- SINDROME
POSTINFECCIOSOS:
LESION CELULAS
CALICIFORMES
- CICATRIZACION POST
MEMBRANAS



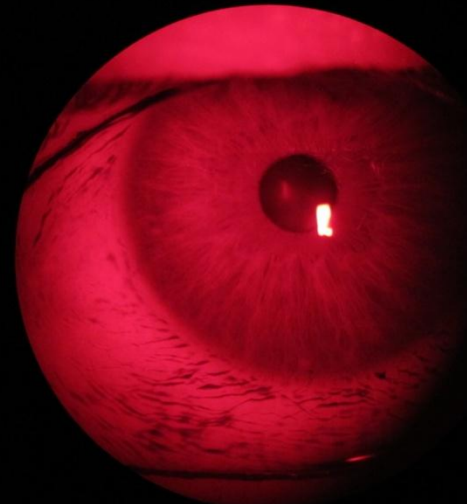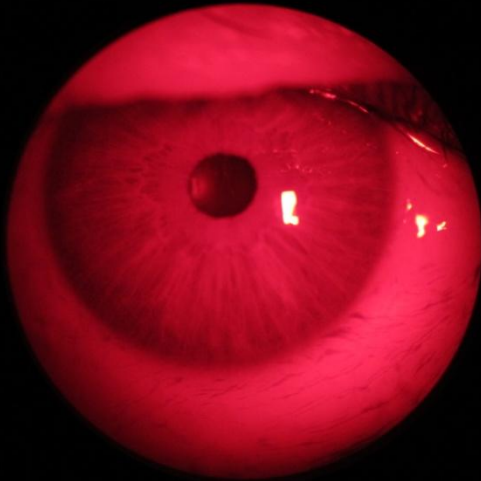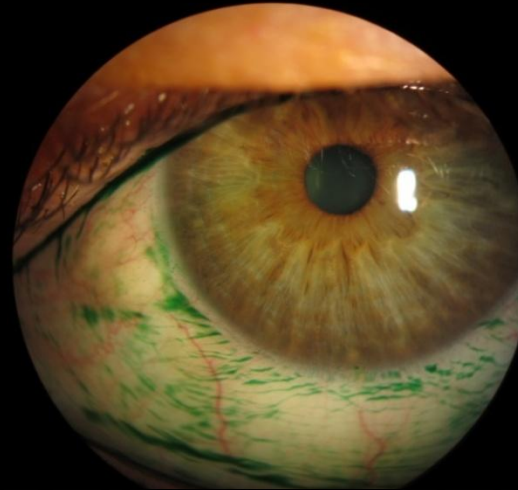
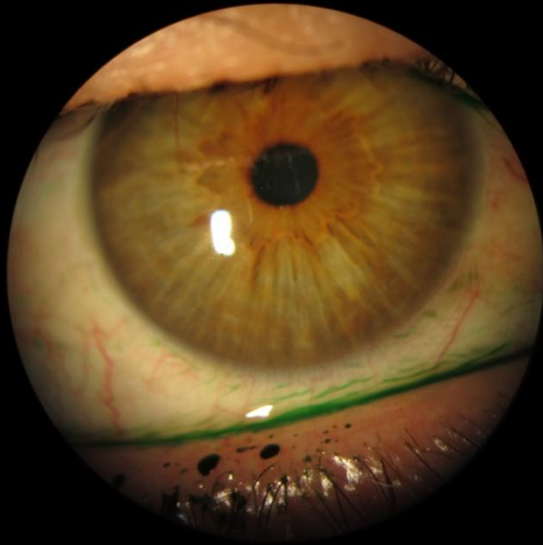BUT ↓ vs ISE..



QCE 2012



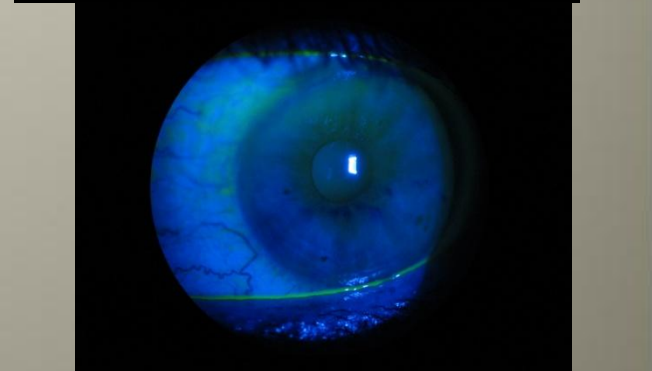
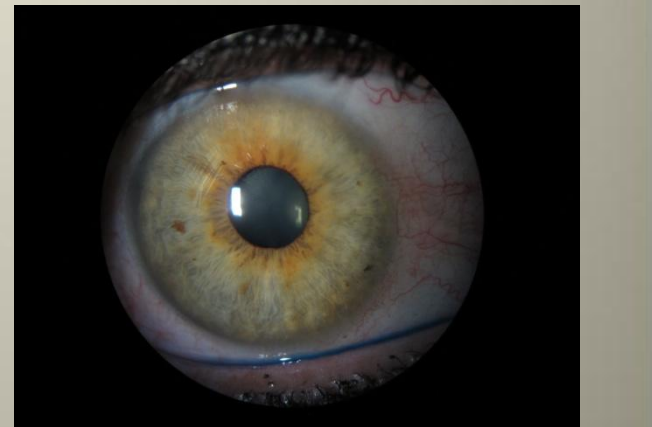
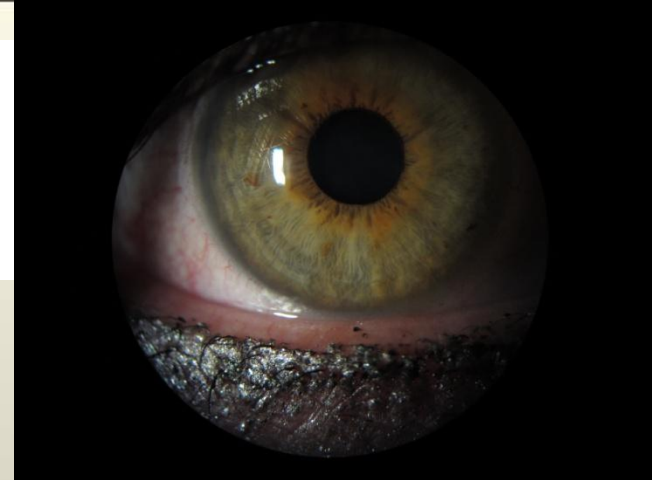
55 a ♂ ISE grado 4 2012
CSA 0.5% feb-jun2012
TCL 0.03% abril 2015-



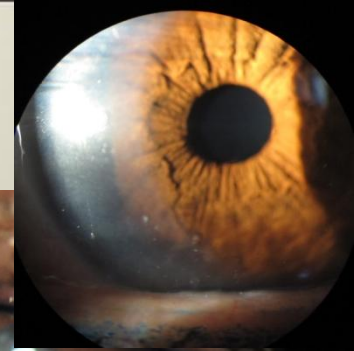
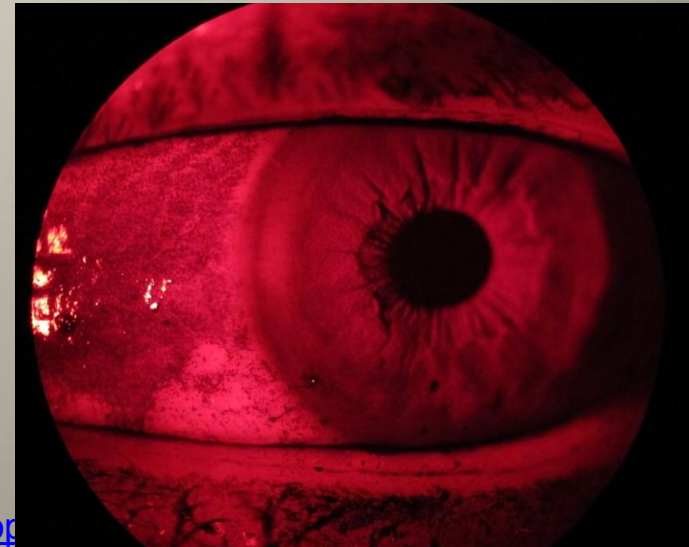
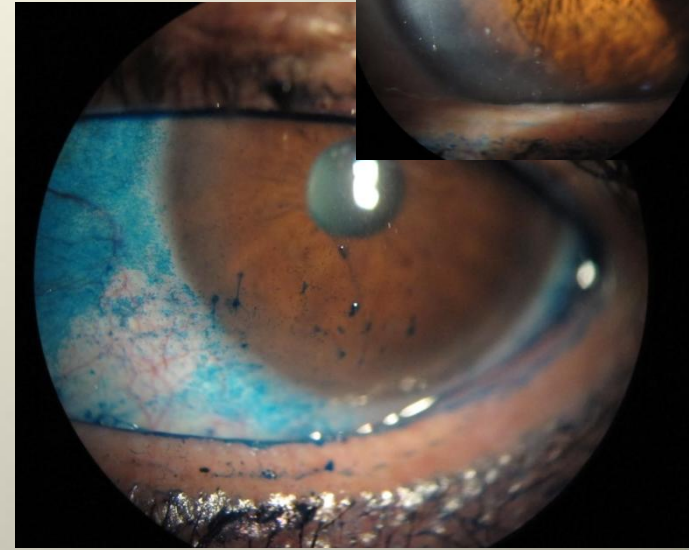
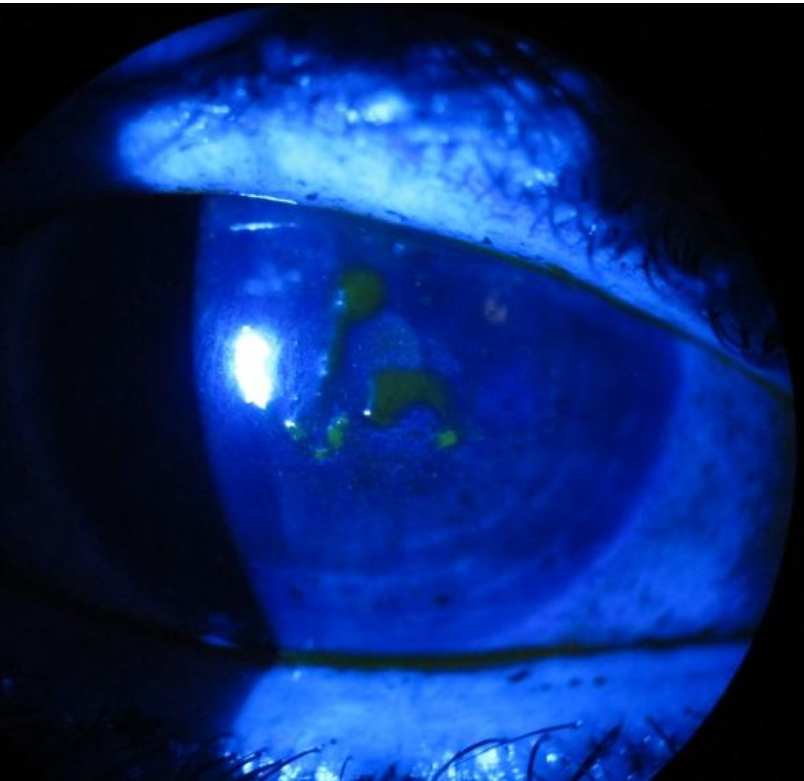
CASO 4 HEPATITIS C

ADDE no SS. Infección de glándula lacrimal

- 40 a ♀ HCV . NAIVE. F0-F1. GENOTIPO 4
- Dic 2014: AV 1 sc ao. Punctata AO, Dolor , Vision borrosa.
T. Schirmer I: 3 /7 mm. BUT 0
- Feb. 2015: CSA 0.05%+ tapones
- 2015-2016 lagrima + CSA
- 2017 solo **CSA 0,05% cada 12 hs .**
Test de Schirmer I: 12 mm ao.
Ausencia Queratitis.BUT : 7"
- 10- 47% de pacientes con HCV
Síndrome Sicca.

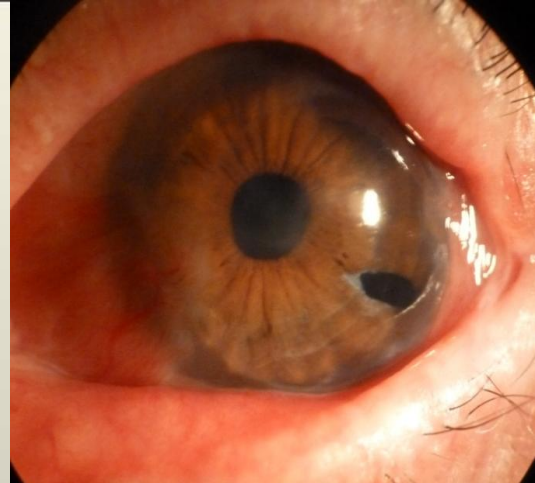
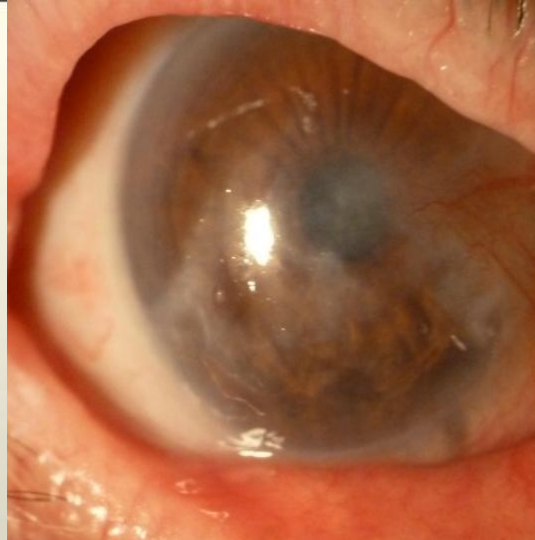
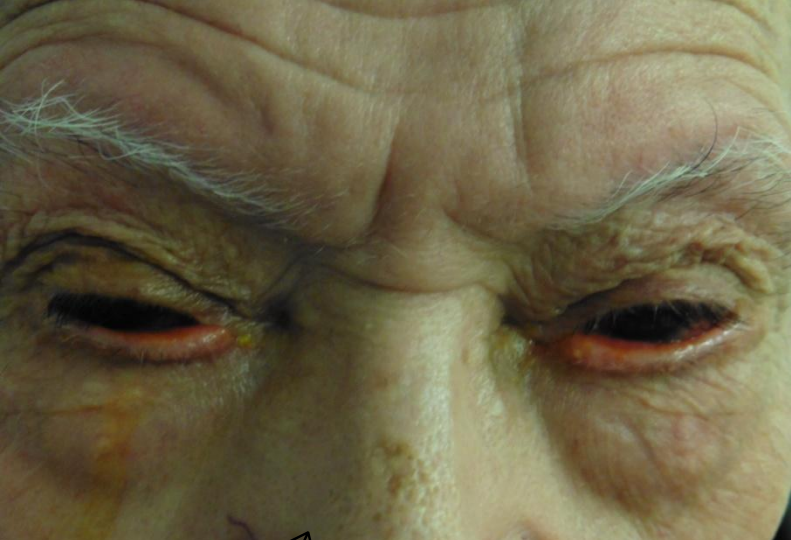
CASO 5: SJÖGREN + AR + TCL

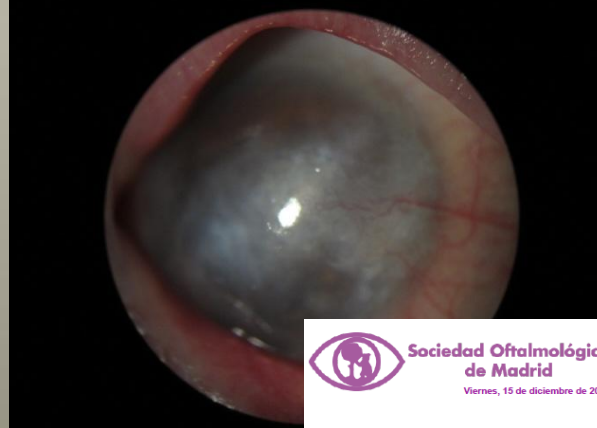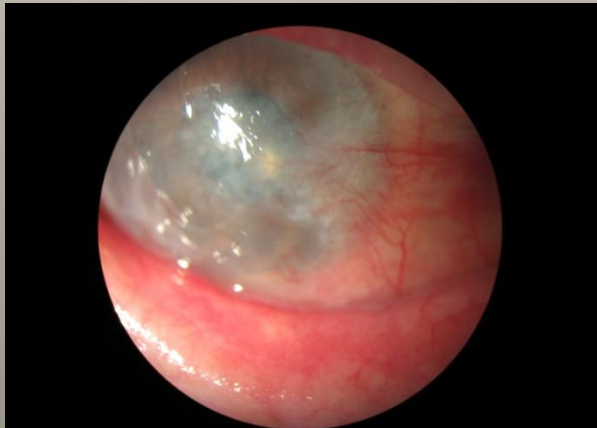
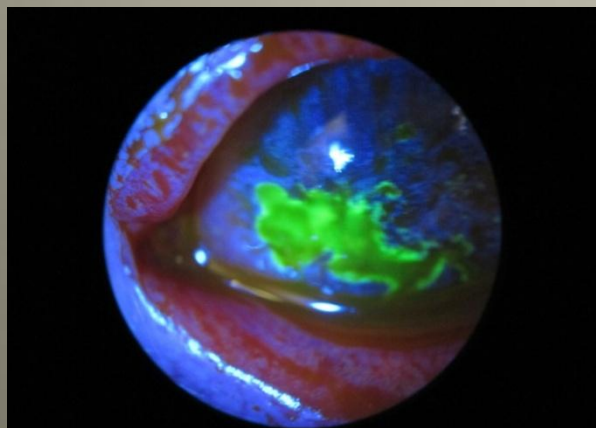


[Treatment of Sjögren's syndrome dry eye using 0.03% tacrolimus eye drops: a randomized study.](#)

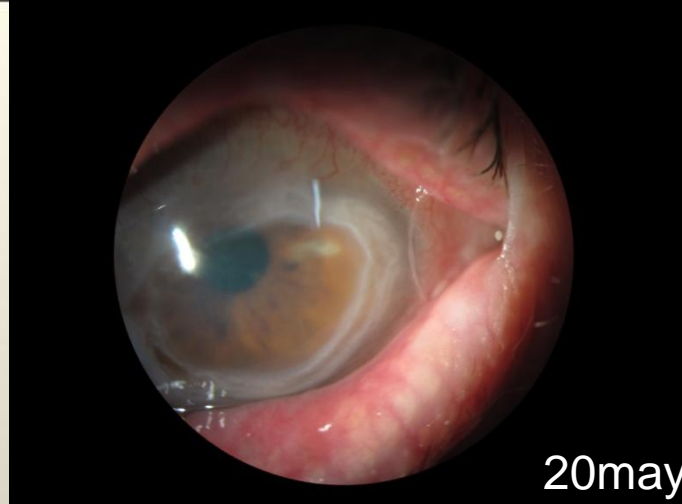
Moscovici BK, Holzchuh R, Sakassegawa-Naves FE, Hoshino-Ruiz DR, Albers MB, Santo RM. Cont Lens Anterior Eye. 2015 Oct;38(5):373-8



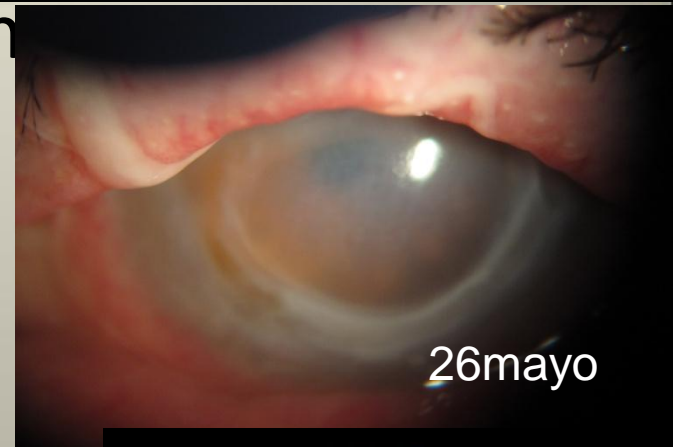- 78 a ♂ AR+ SS+PSORIASIS+EPOC OI QPP 2005
- MAVC CD AO **TCL AO 2013** - MAVC 0,05/0,25
- OD ULCERA 2014 = PCR HERPES POSITIVA.
- SUSPENDEMOS TCL OD + ACICLOVIR



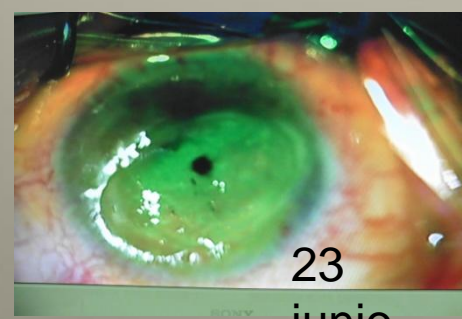
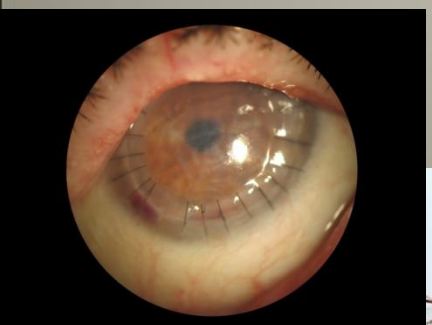- 90 a ♂ AR +DMAE OD + Ectropion inoperable
- PUK OI Mayo 2016
- Reumatólogo Tto sistémico
- **CSA** → **TCL**.... Mala evolución
- Cianoacr. +QPP+MA
- Cultivos + . AP: HSV



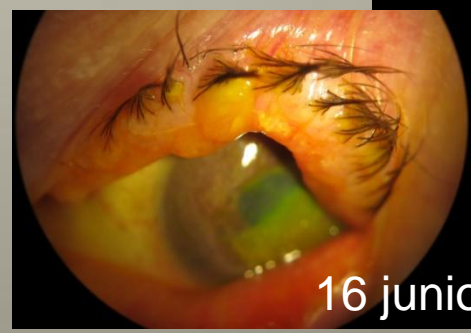20may



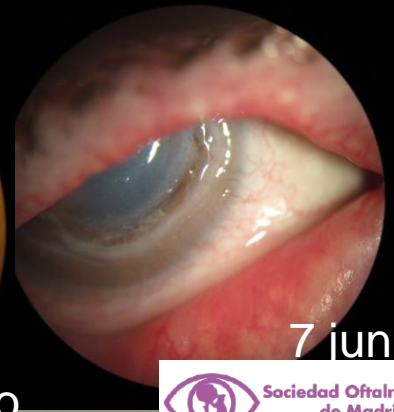26mayo



23 junio



16 junio

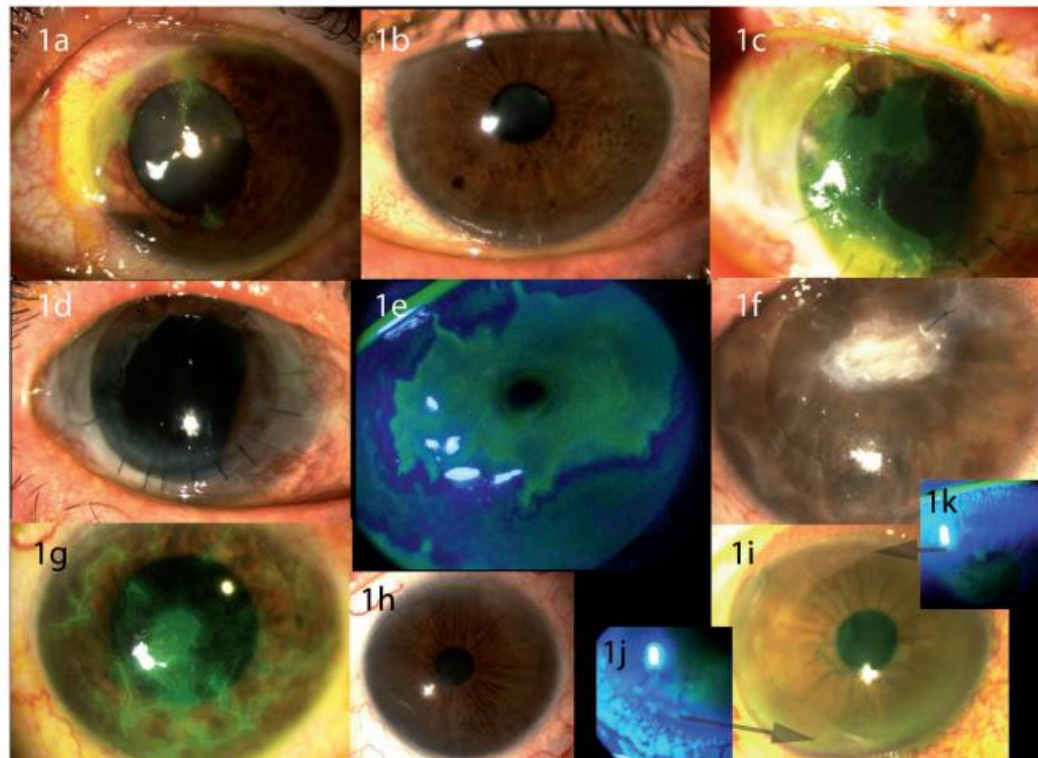


7 junio

Herpes Simplex Keratitis in Rheumatoid Arthritis Patients

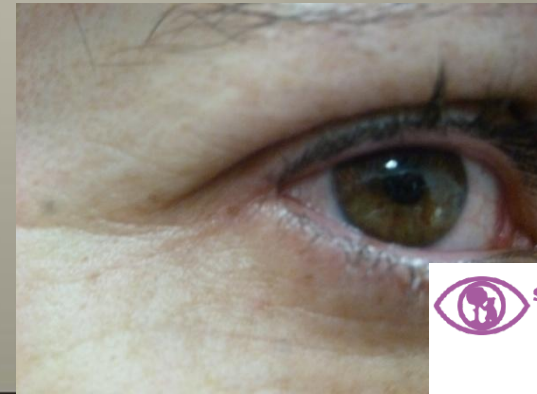
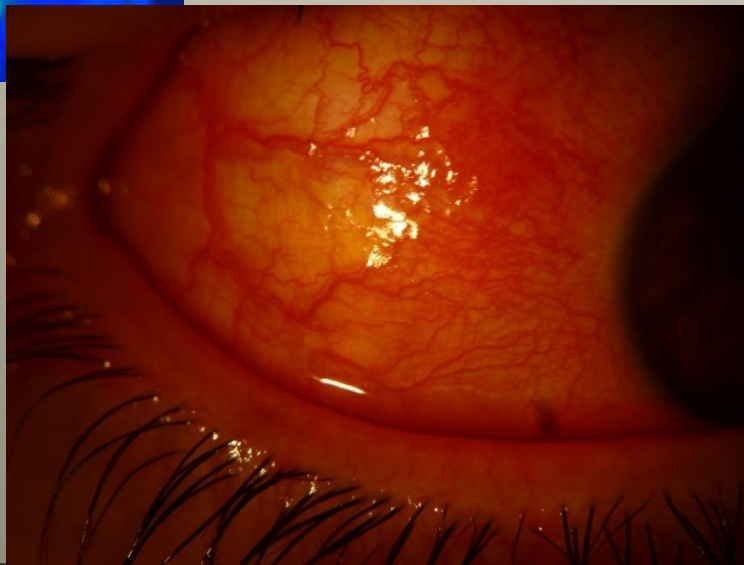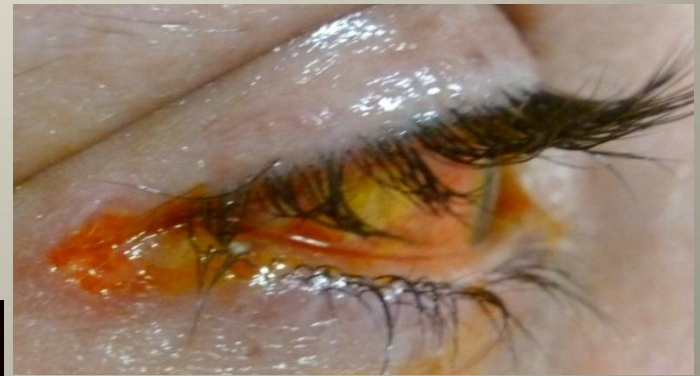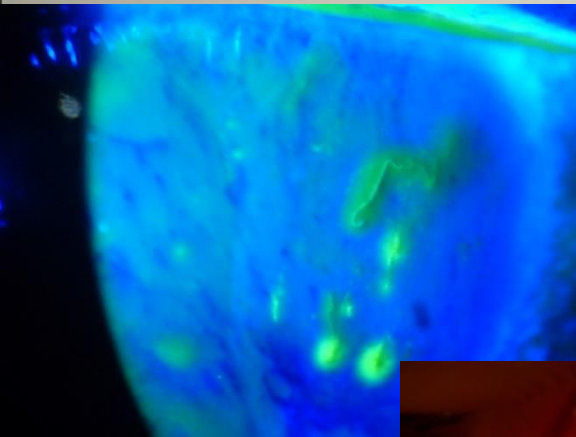
Paula Larrañaga Fragoso, MD¹, Ana Boto de los Bueis, MD¹,
Luciano Bravo Ljubetic, MD¹, Almudena Del Hierro Zarzuelo, MD¹,
M. Pilar Romero Gómez, MD², and Marta Mora Rillo, MD³

¹Department of Ophthalmology, IdiPAZ – Hospital Universitario La Paz, Madrid, Spain, ²Department of Microbiology, IdiPAZ – Hospital Universitario La Paz, Madrid, Spain, and ³Department of Infectious Disease, IdiPAZ – Hospital Universitario La Paz, Madrid, Spain



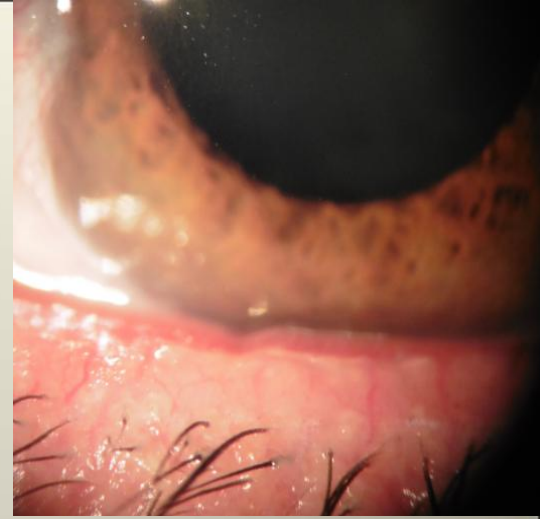
July 2016

- Precaución con el TACROLIMUS en pacientes con queratitis en el contexto de Síndrome de Sjögren y AR . Igualmente en pacientes con AP de infección herpética..

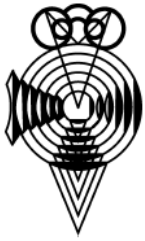

CASO 6 PSORIASIS

- Facial es poco frecuente. (Placas en Párpado).
- **Blefaritis /DGM /Ojo seco EDA**
- Conjuntivitis crónica , xerosis.
- Triquiasis, simblefaron.
- Queratitis punctata, melting, PUK.
- Uveítis anterior (AP) , Corioretinopatía de Birdshot
- Efectos secundarios de fármacos isotretinoína y MTX



Rehal B, Modjtahedi BS, Morse LS, Schwab IR, Maibach HI.
Ocular psoriasis. J Am Acad Dermatol. 2011 Dec;65(6):1202-1



Short communication

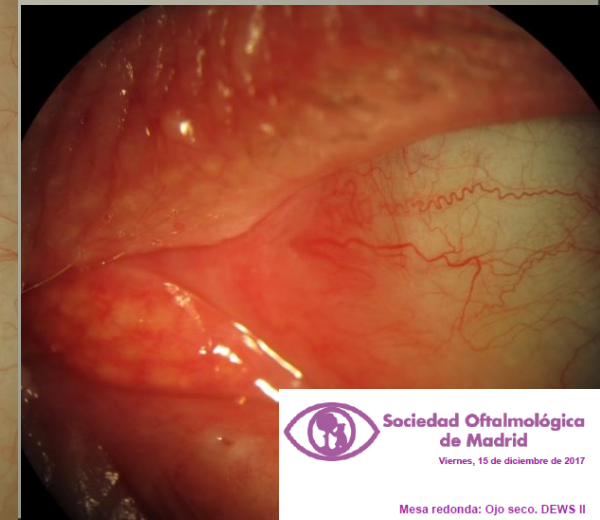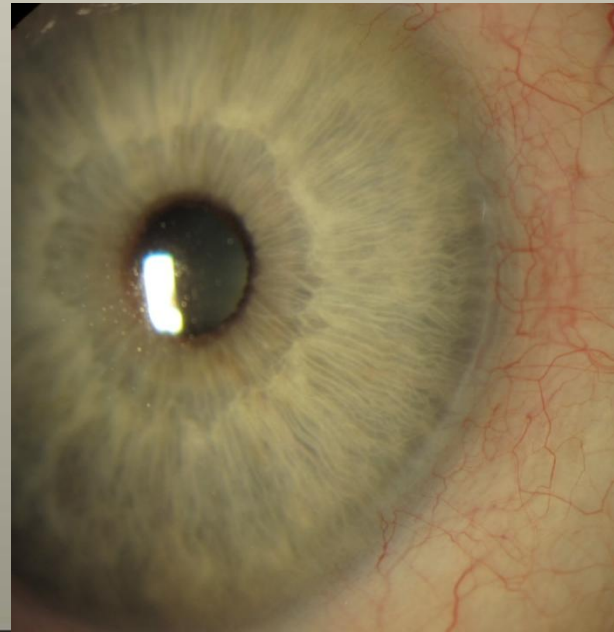
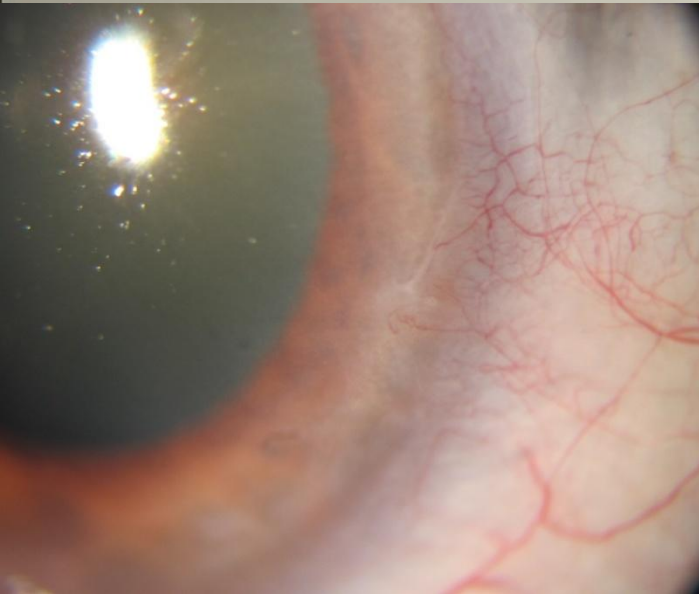
Topical tacrolimus 0.03% for the treatment of ocular psoriasis[☆]



P. Rodríguez-Ausín^{a,*}, D. Antolín-García^a, M. Ruano del Salado^b, C. Hita-Antón^a

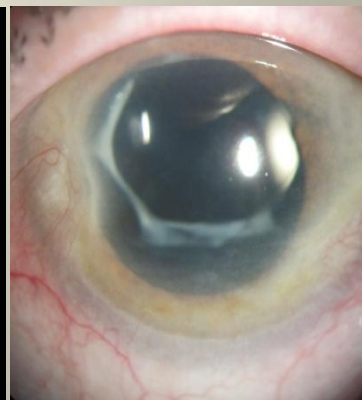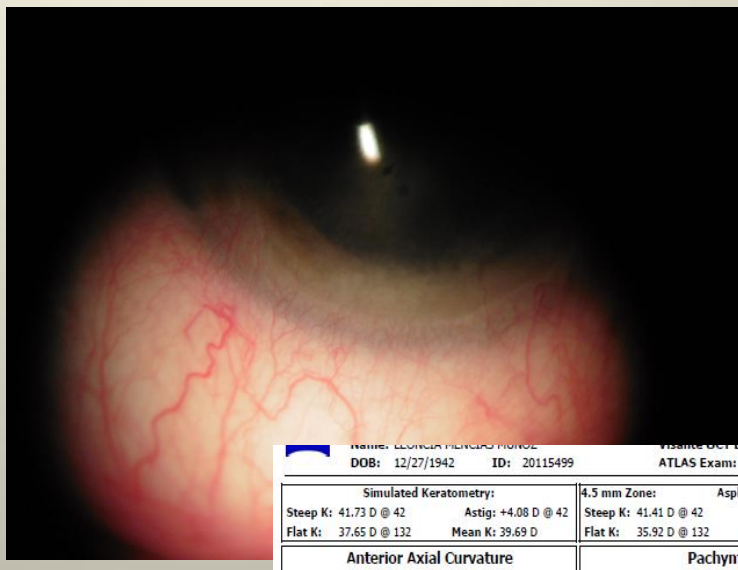
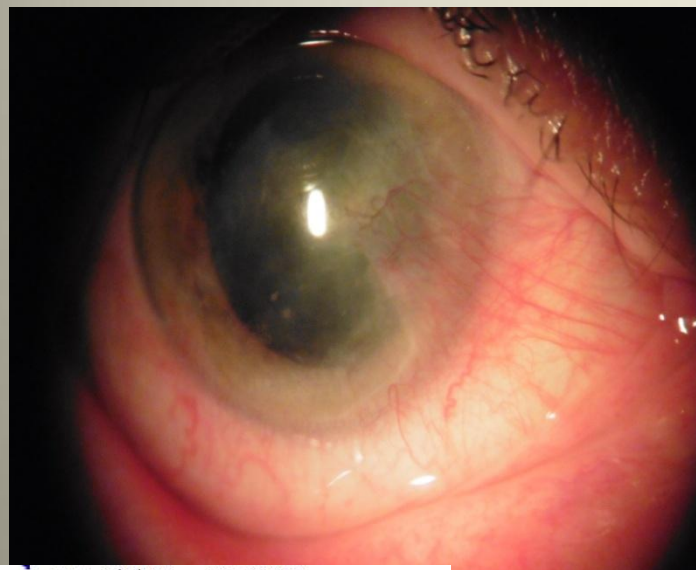^a Departamento de Oftalmología, Hospital Universitario de Torrejón, Torrejón de Ardoz, Madrid, Spain

^b Departamento de Dermatología, Hospital Universitario de Torrejón, Torrejón de Ardoz, Madrid, Spain



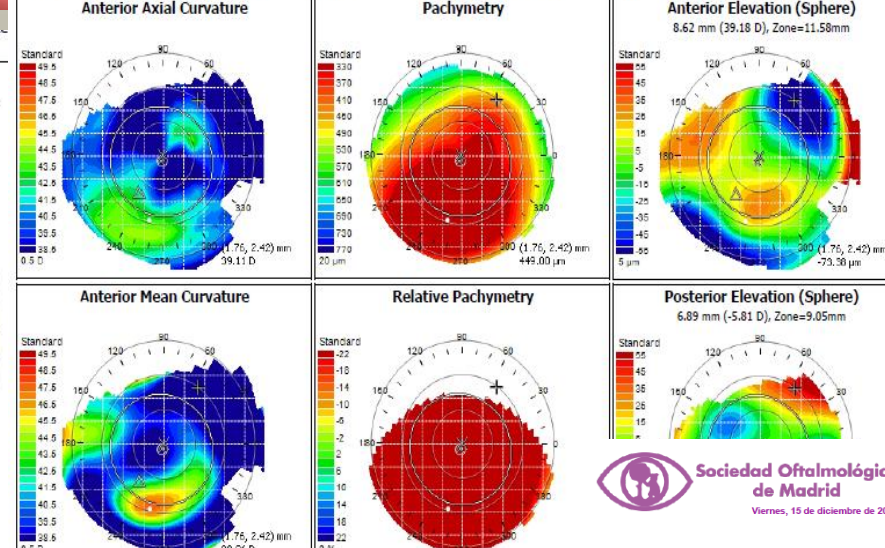
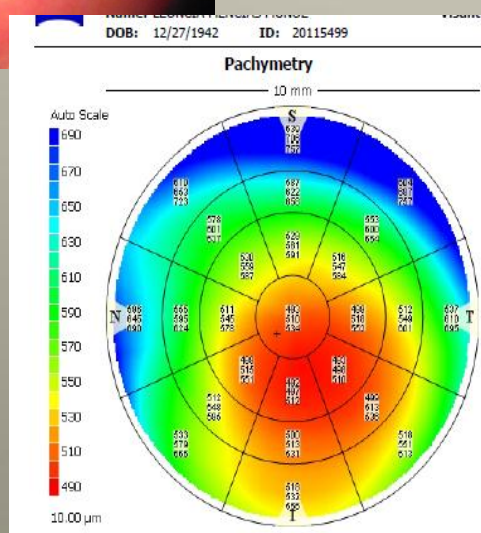
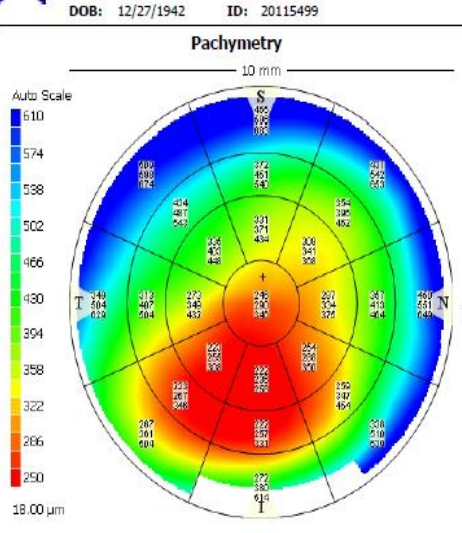
♀ 70 a. Refiere dolor y enrojecimiento ocular toda la vida . CSA en aceite de maíz .

Pseudopterygium ao .Ectasia secundaria od .Adelgazamiento corneal. Catarata ao.

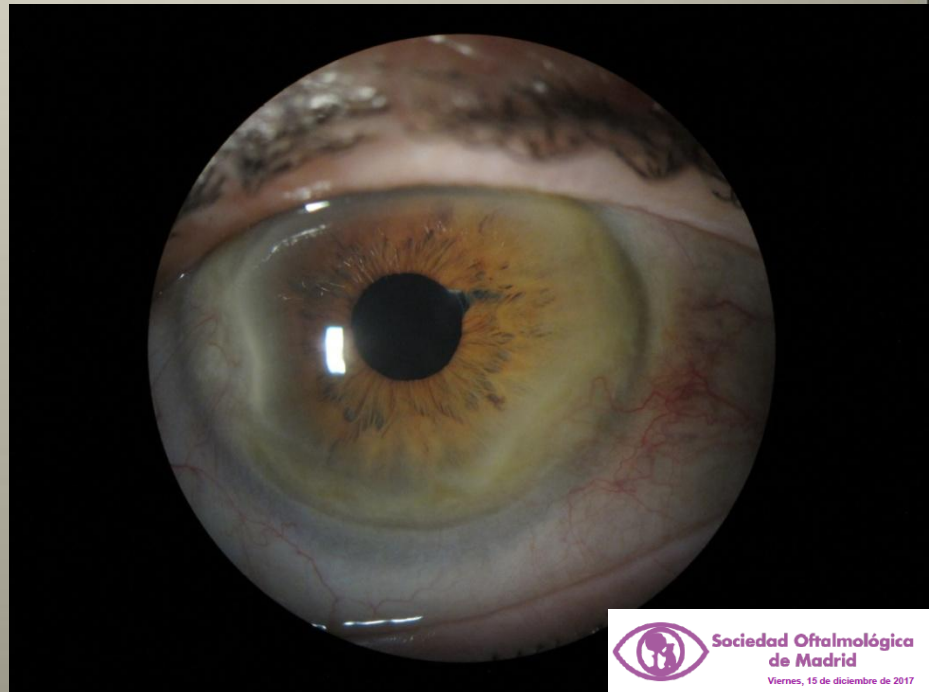
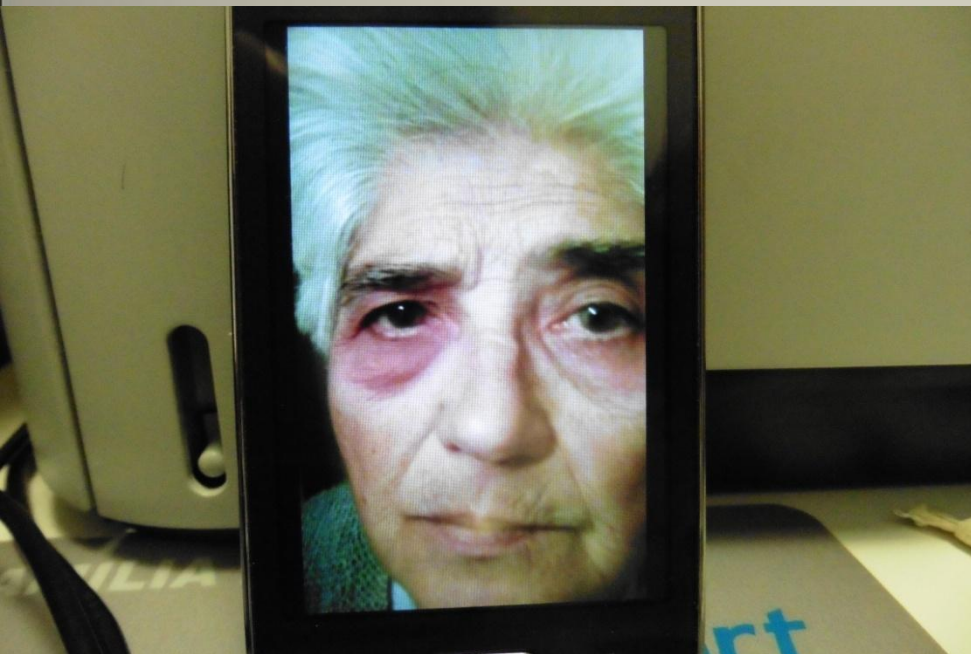
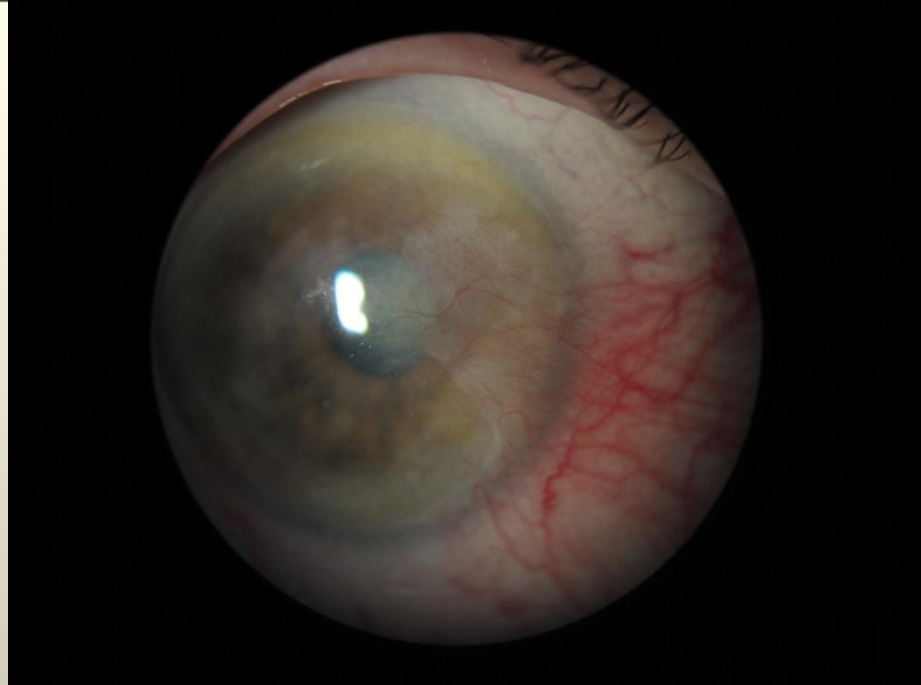


Nombre: LEONOR FLORES FONSECA Visitas OCU Exami: 05/20/2015 12:00:00 PM ANTERIOR SEGMENT IMAGING
 DOB: 12/27/1942 ID: 20115499 ATLAS Exam: 05/20/2015 08:00:46 AM

Simulated Keratometry: Steep K: 41.73 D @ 42 Astig: +4.08 D @ 42 Flat K: 37.65 D @ 132 Mean K: 39.69 D		4.5 mm Zone: Steep K: 41.41 D @ 42 Astig: +5.49 D @ 42 Flat K: 35.92 D @ 132 Mean K: 38.67 D	Asphericity Q: -0.76 Astig: +5.49 D @ 42	Pachy Min: 221 µm WTW: 12.8 mm Pupil Dia: 4.9 mm Spherical aberration Z(4,0): 0.614 µm (@ 6mm)
---	--	---	---	--



TCL 2013- Eritema por alcohol



¡Gracias por su atención !



pazrausin@telefonica.net



Sociedad Oftalmológica
de Madrid

Viernes, 15 de diciembre de 2017

Mesa redonda: Ojo seco. DEWS II