

Tratamientos biológicos en inflamación orbitaria (medicina basada en la evidencia)

Carmen Navarro Perea

Servicio de Oftalmología.Hospital 12 de Octubre




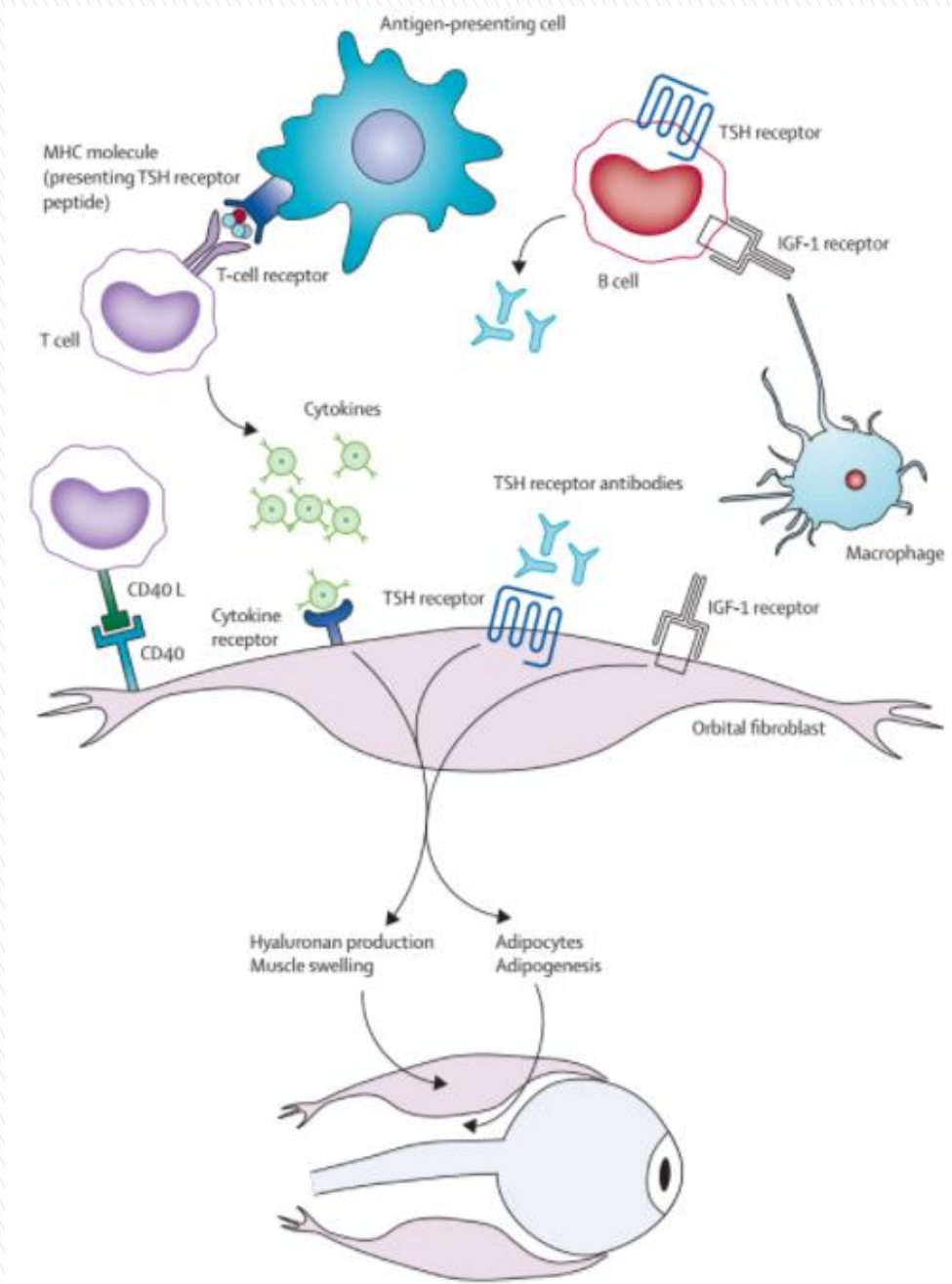
Hospital Universitario
12 de Octubre

Oftalmopatía tiroidea:

- ▶ Es una ENFERMEDAD INFLAMATORIA AUTOINMUNE caracterizada por engrosamiento de los músculos extraoculares, aumento de la grasa orbitaria y del volumen del tejido conectivo orbitario.
- ▶ Se asocia a la enfermedad de Graves (90%), con la tiroiditis de Hashimoto (3%), en el hipotiroidismo primario (1%) o incluso en ausencia de disfunción tiroidea (6%).

Epidemiología:

- ▶ 6 veces más común en mujeres.
 - ▶ La edad media es de 43 años.
 - ▶ 7 veces mayor en los fumadores.
- 




Immunopatología de la Orbitopatía de Graves.


Advances in treatment of active, moderate-to-severe Graves' ophthalmopathy

Clinical Activity Score (CAS)

Score: máximo: 7. Si es ≥ 3 indica actividad de oftalmopatía de la OT

1. ¿Ha tenido dolor ocular espontáneo durante las últimas 4 semanas ? (dolor opresivo retrobulbar)
 2. Ha tenido dolor con los movimientos oculares durante las últimas 4 semanas?
 3. ¿Tiene eritema palpebral?
 4. ¿Tiene hiperemia conjuntival de al menos un cuadrante?
 5. ¿Tiene edema palpebral?
 6. ¿Tiene edema caruncular?
 7. ¿Tiene quemosis?
- 

¿Por qué usar biológicos?

- ▶ Orbitopatía tiroidea moderada-severa sigue siendo un reto terapéutico.
 - ▶ Primera línea: glucocorticoides a altas dosis.
 - ▶ Segunda línea: radioterapia, inmunosupresores (metotrexato, azatioprina, micofenolato mofetil, ciclosporina)
 - ▶ La falta de respuesta e intentar frenar la cascada inflamatoria ha llevado al estudio de los biológicos en esta enfermedad inflamatoria
- 

Rituximab:

- ▶ Anticuerpo monoclonal anti-CD20

Rituximab:


- ▶ Anticuerpo monoclonal anti-CD20

Thyroid. 2006 Jul;16(7):709-10.

Treatment-resistant severe, active Graves' ophthalmopathy successfully treated with B lymphocyte depletion.

El Fassi D, Nielsen CH, Hasselbalch HC, Hegedüs L.

PMID: 16889501 DOI: [10.1089/thy.2006.16.709](https://doi.org/10.1089/thy.2006.16.709)



Rituximab:

- ▶ Anticuerpo monoclonal anti-CD20

Thyroid. 2006 Jul;16(7):709-10.

Treatment-resistant severe, active Graves' ophthalmopathy successfully treated with B lymphocyte depletion.

El Fassi D, Nielsen CH, Hasselbalch HC, Hegedüs L.

PMID: 16889501 DOI: [10.1089/thy.2006.16.709](https://doi.org/10.1089/thy.2006.16.709)

Eur J Endocrinol. 2006 Apr;154(4):511-7.

Efficacy of rituximab treatment for thyroid-associated ophthalmopathy as a result of intraorbital B-cell depletion in one patient unresponsive to steroid immunosuppression.

Salvi M¹, Vannucchi G, Campi I, Rossi S, Bonara P, Sbrozzi F, Guastella C, Avignone S, Pirola G, Ratiglia R, Beck-Peccoz P.

Rituximab:

- ▶ Anticuerpo monoclonal anti-CD20

SPECIAL FEATURE

Clinical Review

Potential Utility of Rituximab for Graves' Orbitopathy

Mario Salvi, Guia Vannucchi, and Paolo Beck-Peccoz

Graves' Orbitopathy Center, Endocrinology, Fondazione Cà Granda, Department of Clinical and Community Sciences, University of Milan, 20122 Milan, Italy

Rituximab:

- ▶ Anticuerpo monoclonal anti-CD20

J Clin Endocrinol Metab. 2015 Feb;100(2):432-41. doi: 10.1210/jc.2014-2572. Epub 2014 Oct 24.

Randomized controlled trial of rituximab in patients with Graves' orbitopathy.

Stan MN¹, Garrity JA, Carranza Leon BG, Prabin T, Bradley EA, Bahn RS.

From Community Services, University of Miami, 20120 Miami, Fla

Address Community Services, University of Miami, 20120 Miami, Fla

Rituximab:

- ▶ Anticuerpo monoclonal anti-CD20

J Clin Endocrinol Metab. 2015 Feb;100(2):432-41. doi: 10.1210/jc.2014-2572. Epub 2014 Oct 24.

Randomized controlled trial of rituximab in patients with Graves' orbitopathy.

Stan MN¹, Garrity JA, Carranza Leon BG, Prabin T, Bradley EA, Bahn RS.

J Clin Endocrinol Metab. 2015 Feb;100(2):422-31. doi: 10.1210/jc.2014-3014. Epub 2014 Dec 15.

Efficacy of B-cell targeted therapy with rituximab in patients with active moderate to severe Graves' orbitopathy: a randomized controlled study.

Salvi M¹, Vannucchi G, Currò N, Campi I, Covelli D, Dazzi D, Simonetta S, Guastella C, Pignataro L, Avignone S, Beck-Peccoz P.

Teprotumumab

- ▶ Anticuerpo monoclonal anti-IGF-1 R

J Clin Endocrinol Metab. 2014 Sep;99(9):E1635-40. doi: 10.1210/jc.2014-1580. Epub 2014 May 30.

Teprotumumab, an IGF-1R blocking monoclonal antibody inhibits TSH and IGF-1 action in fibrocytes.

Chen H¹, Mester T, Raychaudhuri N, Kauh CY, Gupta S, Smith TJ, Douglas RS.

Teprotumumab

- ▶ Anticuerpo monoclonal anti-IGF-1 R

[J Clin Endocrinol Metab](#). 2014 Sep;99(9):E1635-40. doi: 10.1210/jc.2014-1580. Epub 2014 May 30.

Teprotumumab, an IGF-1R blocking monoclonal antibody inhibits TSH and IGF-1 action in fibrocytes.

[Chen H](#)¹, [Mester T](#), [Raychaudhuri N](#), [Kauh CY](#), [Gupta S](#), [Smith TJ](#), [Douglas RS](#).

[N Engl J Med](#). 2017 May 4;376(18):1748-1761. doi: 10.1056/NEJMoa1614949.

Teprotumumab for Thyroid-Associated Ophthalmopathy.

[Smith TJ](#)¹, [Kahaly GJ](#)¹, [Ezra DG](#)¹, [Fleming JC](#)¹, [Dailey RA](#)¹, [Tang RA](#)¹, [Harris GJ](#)¹, [Antonelli A](#)¹, [Salvi M](#)¹, [Goldberg RA](#)¹, [Gigantelli JW](#)¹, [Couch SM](#)¹, [Shriver EM](#)¹, [Hayek BR](#)¹, [Hink EM](#)¹, [Woodward RM](#)¹, [Gabriel K](#)¹, [Magni G](#)¹, [Douglas RS](#)¹.

Infliximab, etanercept y adalimumab

- ▶ Inhibidores del Factor de Necrosis Tumoral (anti- TNF α)
- ▶ No hay ensayos clínicos controlados y aleatorizados

Eye (Lond). 2005 Dec;19(12):1286-9.

The effect of etanercept on Graves' ophthalmopathy: a pilot study.

Paridaens D¹, van den Bosch WA, van der Loos TL, Krenning EP, van Hagen PM.

Infliximab, etanercept y adalimumab

- ▶ Inhibidores del Factor de Necrosis Tumoral (anti- TNF α)
- ▶ No hay ensayos clínicos controlados y aleatorizados

ORBIT, 2005 Jun;24(2):117-9.

[Orbit](#). 2005 Jun;24(2):117-9.

Infliximab: a novel treatment for sight-threatening thyroid associated ophthalmopathy.

[Durrani OM](#)¹, [Reuser TQ](#), [Murray PI](#).

Infliximab, etanercept y adalimumab

- ▶ Inhibidores del Factor de Necrosis Tumoral (anti- TNF α)
- ▶ No hay ensayos clínicos controlados y aleatorizados

[Ophthalm Plast Reconstr Surg](#). 2014 Sep-Oct;30(5):415-9. doi: 10.1097/IOP.0000000000000211.

Adalimumab as steroid-sparing treatment of inflammatory-stage thyroid eye disease.

[Ayabe R](#)¹, [Rootman DB](#), [Hwang CJ](#), [Ben-Artzi A](#), [Goldberg R](#).

Tocilizumab:

- ▶ Anticuerpo monoclonal anti-IL6

Ophthal Plast Reconstr Surg. 2014 Mar-Apr;30(2):162-7. doi: 10.1097/IOP.0000000000000037.

Treatment of active corticosteroid-resistant graves' orbitopathy.

Pérez-Moreiras JV¹, Alvarez-López A, Gómez EC.

Tocilizumab:

▶ Anticuerpo monoclonal anti-IL6



Tocilizumab Treatment in Graves' Ophthalmopathy (Graves' Orbitopathy or Thyroid Eye Disease) (GRC)

This study has been completed.

Sponsor:

Hospital Clinico Universitario de Santiago

ClinicalTrials.gov Identifier:

NCT01297699

First Posted: February 17, 2011

Last Update Posted: January 20, 2016


⚠ The safety and scientific validity of this study is the responsibility of the study sponsor and investigators. Listing a study does not mean it has been evaluated by the U.S. Federal Government. Read our [disclaimer](#) for details.

Collaborator:


Fundación Ramón Domínguez

Information provided by (Responsible Party):

Dr. Juan Jesus Gomez-Reino Carnota, Hospital Clinico Universitario de Santiago



Conclusiones:

- ▶ Rituximab tratamiento de segunda línea en casos refractarios a corticoesteroides
 - ▶ Tocilizumab: pendiente de resultados en orbitopatía moderada-severa que amenaza visión, resistente a terapia con corticoides o diabeticos
 - ▶ Infliximab, etanercept y adalimumab: actualmente no indicados
 - ▶ Teprotumumab: buenos resultados en orbitopatía moderda-severa a la espera de resultados a largo plazo
- 

A nighttime photograph of the River Segura in Valencia, Spain. The scene is illuminated by city lights, with the most prominent feature being the Tower of the City of Arts and Sciences, a cylindrical stone tower with a crenellated top, brightly lit and reflected in the water. Several white boats with lights are docked along the riverbank. In the background, a bridge with lights spans the river, and the city skyline is visible under a twilight sky. The overall atmosphere is serene and urban.

Muchas gracias